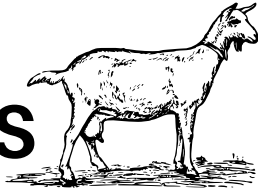


# EVENTS & FAIRS CHECKLIST: GOATS



## OFFICIAL CERTIFICATE OF VETERINARY INSPECTION (CVI)

- Is a current 2026 season NE CVI with the destination listed on it.  
-OR-  
CVI is written specifically for the event and is dated within the past 30 days.
- All animal ID listed on the CVI matches the animal ID on the animals present.
- Appears to be unaltered.
- Remember, Maine animals traveling in state do not need a CVI!

## SIGNS OF POOR ANIMAL HEALTH

- Must show no evidence of disease: diarrhea, runny nose, cough etc.
- No recent castration evidence.
- No wool/hair loss, including "healing" ringworm lesions, lice, or mange.
- No scabs, crusts, pimples, blisters, open skin, open wounds/abscesses.
- No pink eye or eye injuries.
- No mastitis
- No retained placentas
- No signs of neurological impairment
- No signs of lameness or pain (teeth grinding/hunched posture/dull/head pressing).

## ANIMAL IDENTIFICATION

- All animals of any age must have USDA official ID.
- Goats must be identified with an appropriate scrapie tag properly secured in the ear or breed registration papers with matching tattoos +/- microchip
- Microchip numbers must start 840.
- Microchips must be implanted in the tail or behind the ear.

## ANIMAL CONDITION

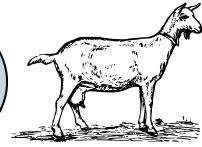
- Body condition score should be within the healthy range.
- Ideal BCS range for goats is 2.5-4 of 5.

## RECOMMENDED VACCINES

- Rabies all goats over 12 weeks old, remember it is valid for 1 year!
- Appropriate respiratory vaccines.
- Appropriate tetanus/clostridial vaccines.

# SIGNS OF DISEASE REFERENCE

## BASIC BODY CONDITION SCORING- GOATS



Scan the QR code to watch a Youtube video on Body Condition Scoring DAIRY Goats

Scan the QR code to watch a Youtube video on Body Condition Scoring MEAT Goats

### PACK GOATS SHOULD BE ASSESSED ACCORDING TO BREED

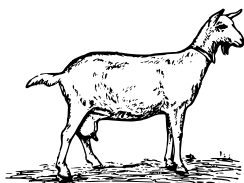
| Body Condition Score for Dairy Goats* |         |  |   |  |  |
|---------------------------------------|---------|--|---|--|--|
|                                       | BCS 1** | Lumbar spine   | Ribs  | Sternum  |  |
| Emaciated                             |         | <b>Top of spine:</b> clearly visible, can easily be pinched. Deep depression between each vertebrae.<br><b>Short ribs:</b> form a continuous shelf that fingers can grasp. Deep depression between each.<br><b>Transition:</b> no fat and little muscle is felt between the top of the spine and short ribs. | <b>Ribs:</b> Clearly visible. Fingers easily penetrate space between ribs.  | <b>Cartilage:</b> easily felt.<br><b>Fat pad:</b> can easily be grasped between thumb and forefinger and moved side to side. |  |
| Thin                                  |         | <b>Top of spine:</b> visible, some muscle can be felt between skin and bone.<br><b>Short ribs:</b> form a shelf that fingers can grasp.<br><b>Transition:</b> deep depression from the top of the spine to the short ribs.   | <b>Ribs:</b> some can be seen. Fingers easily penetrate space between ribs.   | <b>Cartilage:</b> not easily felt.<br><b>Fat pad:</b> can be grasped and moved slightly from side to side.                   |  |
| Ideal                                 |         | <b>Top of spine:</b> not prominent, slight hollow between vertebrae. Cannot easily be grasped.<br><b>Short ribs:</b> shelf is slightly noticeable, cannot be grasped.<br><b>Transition:</b> smooth slope from top of the spine to short ribs.  | <b>Ribs:</b> difficult to see. Space between ribs felt with pressure.   | <b>Cartilage:</b> barely felt.<br><b>Fat pad:</b> wide and thick, it can be grasped, but has very little movement.           |  |
| Overweight                            |         | <b>Top of spine:</b> cannot be seen. No indent between vertebrae. Top of spine is flat and cannot be grasped.<br><b>Short ribs:</b> no ridge or shelf present.<br><b>Transition:</b> rounded from the top of the spine to the short ribs.  | <b>Ribs:</b> cannot be seen. Side of the animal is flat in appearance. Space between ribs only felt with strong pressure. | <b>Cartilage:</b> cannot be felt.<br><b>Fat pad:</b> difficult to grasp, cannot be moved side to side.                       |  |
| Obese                                 |         | <b>Top of spine:</b> buried in fat, slight indent surrounded by bulging fat. Rump looks like the top of a heart. Individual vertebrae cannot be felt.<br><b>Short ribs:</b> individual vertebrae cannot be felt.<br><b>Transition:</b> fat bulges out from the top of the spine to the short ribs.           | <b>Ribs:</b> not visible. Space between ribs cannot be felt.  | <b>Cartilage:</b> cannot be felt.<br><b>Fat pad:</b> cannot be grasped or moved.   |  |

| Body Condition Score for Meat Goats* |         |  |   |  |  |
|--------------------------------------|---------|--|---|--|--|
|                                      | BCS 1** | Lumbar spine   | Ribs  | Sternum  |  |
| Emaciated                            |         | <b>Top of spine:</b> clearly visible, can easily be pinched. Deep depression between each vertebrae.<br><b>Short ribs:</b> form a continuous shelf that fingers can grasp. Deep depression between each.<br><b>Transition:</b> no fat and little muscle is felt between the top of the spine and short ribs. | <b>Ribs:</b> Clearly visible. Fingers easily penetrate space between ribs.  | <b>Cartilage:</b> easily felt.<br><b>Fat pad:</b> can easily be grasped between thumb and forefinger and moved side to side. |  |
| Thin                                 |         | <b>Top of spine:</b> visible, some muscle can be felt between skin and bone.<br><b>Short ribs:</b> form a shelf that fingers can grasp.<br><b>Transition:</b> deep depression from the top of the spine to the short ribs.   | <b>Ribs:</b> some can be seen. Fingers easily penetrate space between ribs.   | <b>Cartilage:</b> not easily felt.<br><b>Fat pad:</b> can be grasped and moved slightly from side to side.                   |  |
| Ideal                                |         | <b>Top of spine:</b> not prominent, slight hollow between vertebrae. Cannot easily be grasped.<br><b>Short ribs:</b> shelf is slightly noticeable, cannot be grasped.<br><b>Transition:</b> smooth slope from top of the spine to short ribs.  | <b>Ribs:</b> difficult to see. Space between ribs felt with pressure.   | <b>Cartilage:</b> barely felt.<br><b>Fat pad:</b> wide and thick, it can be grasped, but has very little movement.           |  |
| Overweight                           |         | <b>Top of spine:</b> cannot be seen. No indent between vertebrae. Top of spine is flat and cannot be grasped.<br><b>Short ribs:</b> no ridge or shelf present.<br><b>Transition:</b> rounded from the top of the spine to the short ribs.  | <b>Ribs:</b> cannot be seen. Side of the animal is flat in appearance. Space between ribs only felt with strong pressure. | <b>Cartilage:</b> cannot be felt.<br><b>Fat pad:</b> difficult to grasp, cannot be moved side to side.                       |  |
| Obese                                |         | <b>Top of spine:</b> buried in fat, slight indent surrounded by bulging fat. Rump looks like the top of a heart. Individual vertebrae cannot be felt.<br><b>Short ribs:</b> individual vertebrae cannot be felt.<br><b>Transition:</b> fat bulges out from the top of the spine to the short ribs.           | <b>Ribs:</b> not visible. Space between ribs cannot be felt.  | <b>Cartilage:</b> cannot be felt.<br><b>Fat pad:</b> cannot be grasped or moved.   |  |

\*One unit of Body Condition Score is equivalent to 7-10 kg (15-22 lb)  
\*\*Unit for transport other than under advice of veterinarian

\*One unit of Body Condition Score is equivalent to 7-10 kg (15-22 lb)  
\*\*Unit for transport other than under advice of veterinarian





Scan the QR code  
for more  
information on  
zoonotic goat  
diseases

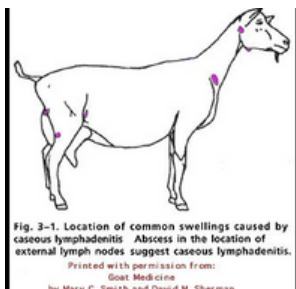
## SHALL NOT PASS LESIONS



**Oral Lesions can be caused by a number of injuries, bacteria and viruses.** At an event there is no way to tell for certain the cause which is why DACF doesn't recommend exhibition of animals with oral lesions at public events. Animals with oral lesions should not be allowed off the trailer and the animal should go home immediately.

**\* Please note scabs can be sources of infection**

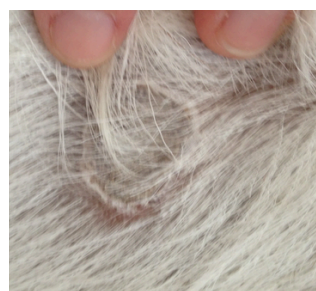**Possible Zoonotic or Infectious Causes: Orf, MRSA, & Other bacteria**



**Abscesses are caused by bacteria or other foreign objects entering the body,** sometimes after the skin is punctured or from internal means. If the abscess is closed it is less risk. Once it is open, the bacteria can be spread rapidly and can cause disease in other animals and people. Without culturing the abscess, which can take weeks for results, DACF recommends these animals be sent home.

**\* Please note pus is a source of infection**


**Possible Zoonotic or Infectious Causes: CL, MRSA, E. coli & Other Bacteria**



**Crusts and hair loss not caused by a collar or feeder have a range of possible causes from external parasites to fungus.** Lice and mange are considered infectious disease and can be visualized with a microscope or flea comb in most cases. Ring worm is another common cause with a distinct rounded boarder pattern. MRSA and other bacteria can cause skin infections and wool/hair loss as well. DACF recommends these animals be sent home.

**\* Please note crusts and fallen hair can be a source of infection**

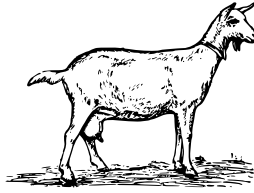
**Possible Zoonotic or Infectious Causes: Mange, Lice, Ringworm, Bacteria**



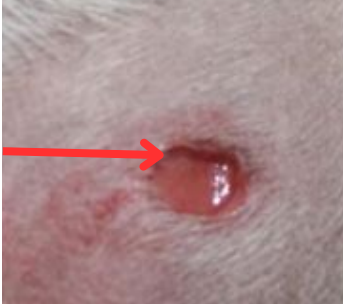**Diarrhea can be from stress or GI infection from viruses or bacteria.** Bloody, green, watery, chronic or severe diarrhea cases can be fatal. DACF recommends these animals be sent home.

**Possible Zoonotic or Infectious Causes: E. coli, Salmonella, Cryptosporidium, Clostridiums, Giardia, Gastrointestinal parasites, Johnes**

# MAINE ANIMAL HEALTH REFERENCE



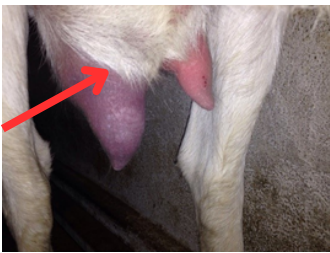
## SHALL NOT PASS LESIONS



**Open wounds are not advisable for public exhibition for the concerns of animal welfare and public perception.** Lesions should be promptly treated appropriately and covered with a bandage whenever possible. Oozing discharge from wounds may contain infectious bacteria.

**\*Please note discharges can be sources of infection**

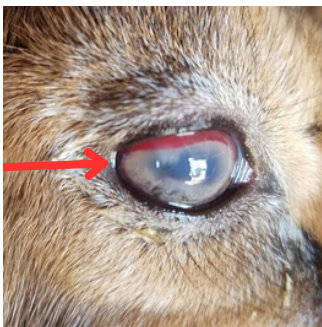
**Possible Zoonotic or Infectious Causes: MRSA, E. coli, CL, Salmonella, Tetanus**



**Mastitis can be painful and sometimes fatal even with treatment.** Mastitis can be an animal welfare and public perception issue. Animals with active mastitis are not fit for exhibition and can pose a public health risk. DACF recommends these animals be sent home for appropriate treatment.

**\*Please note milk is a source of infection**

**Possible Zoonotic or Infectious Causes: CL, MRSA, E. coli, Brucellosis, Tuberculosis, Cryptosporidium, Other Bacteria such as Mycoplasma**




**Eye lesions may be a symptom of concern for public and animal health.**

Trauma lesions and ulcerative diseases of the eye can look similar, advanced diagnostics are needed to make a diagnosis. Injuries and disease of the eye can impair the animal's vision and can cause the animal to become less predictable to handle. DACF recommends these animals be sent home.

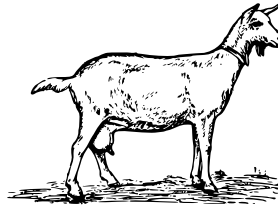
**\*Please note pus/discharge can be a source of infection**

**Possible Zoonotic or Infectious Causes: Pink-eye, CL, Chlamydia, E.coli, Salmonella, Chlamydia, Other Bacteria, MCF, Atypical Orf**



**Fetal membranes and birthing fluids can be vectors for animal and human health diseases.** Animals due to give birth at the event or with retained fetal membranes- DACF recommends these animals be sent home.

**Possible Zoonotic or Infectious Cause: E. coli, Salmonella, Q Fever, Toxoplasmosis, Brucellosis, Chlamydia, Listeriosis, Leptospirosis (urine)**



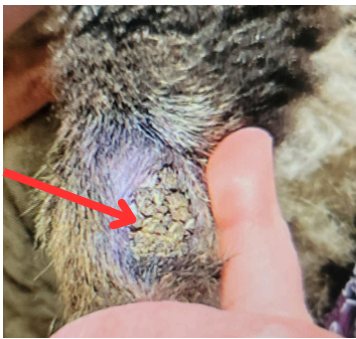## SHALL NOT PASS LESIONS



**Neurological symptoms are usually easy to spot.** Circling, teeth grinding, staggering, star gazing, head pressing, drooling, tongue hanging out of mouth, ear drooped on one side, muscular or facial asymmetry are some common symptoms. Neurological animals should be handled with caution and a veterinarian should be contacted immediately.


**\*Please note discharges can be sources of infection.**

**Possible Zoonotic or Infectious Causes: Rabies, Listeriosis, Botulism, Tetanus, Arboviruses, Scrapie**



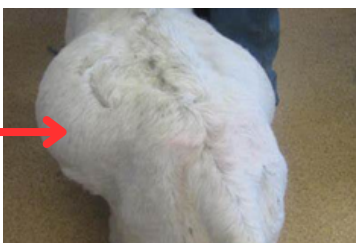**Lameness can have many causes but is an animal health and wellness concern.** It is recommended a veterinarian be consulted once a lame animal is identified. Fractured limbs, hoof rot lesions, severe arthritis, Malignant Catarrhal fever, Lentivirus infection are of concern. Note that some hoof rot pathogens are contagious to other animals. DACF recommends sending "down" or event veterinarian determined lame animals home.

**\*Please note warts, open blisters and discharges are a source of infection**



**Respiratory signs can be serious illness.** Rapid breathing, coughing, teeth grinding, sneezing, wheezing, open mouth breathing, foam around the mouth, watery eyes, panting are all respiratory signs. A veterinarian should be consulted if these symptoms are observed and determine if the cause is stress related or could be due to illness. DACF recommends ill or severely stressed animals be sent home. **\*Please note discharge can be a source of infection**

**Possible Zoonotic or Infectious Causes: CL, Influenza, BRSV, Parainfluenza, Rabies, Mycoplasma & Other Bacteria**



**Bloat can occur from changes in feed/environment as well as from infectious agents like Clostridium Type C.** This condition can be an emergency, a veterinarian should be consulted. DACF recommends sending chronic cases of bloat home.

**Possible Zoonotic or Infectious Causes: Clostridial bacteria**